Cranial Cruciate Ligament Ruptures

Cruciate ligament ruptures are the most common cause of hindlimb lameness in dogs.

The stifle (knee) joint in dogs is a complicated joint depending on multiple structures to provide it with stability in motion. The structures that are affected in this condition are the cruciate ligaments, most commonly the cranial cruciate ligament and the menisci of the stifle.



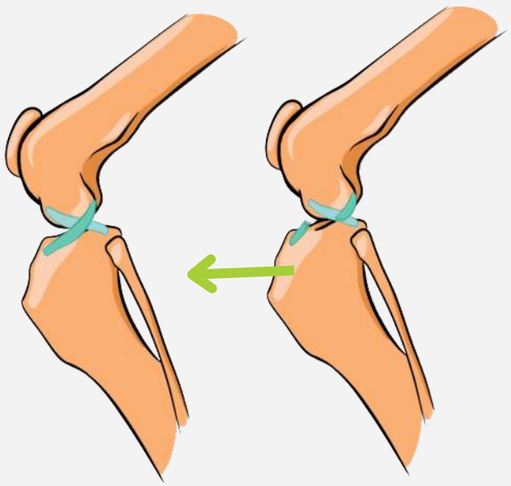

Like people, dogs have two crossed ligaments inside their stifle – cranial and caudal cruciate ligaments. Without these two ligaments, the stifle becomes unstable. The cranial cruciate ligaments prevent the tibia (the larger of two bones supporting weight below the knee) from sliding forward as the dog takes weight.

The menisci are little pads inside the stifle joint that ensure that the bones of the stifle fit together nicely and have a smooth surface to glide on during movement. When the movement of the stifle becomes unstable, the menisci can tear, causing pain and lameness in our dogs.
The cruciate ligament can rupture as a result of trauma or degeneration of the ligament.

AQUACANINE
HYDRO & VETERINARY PHYSIO

© Copyright. All Rights Reserved. Aqua Canine

CREDITS: Artwork: Anna Lloyd | Image: PawProsper